

Recalcitrant Nasal Polyposis: Achievement of Total Remission Following Treatment With Omalizumab

M Guglielmo,¹ C Gulotta,¹ F Mancini,² M Sacchi,² F Tarantini³

¹ Department of Pulmonology – Respiratory Pathophysiology, AOU San Luigi Gonzaga, Orbassano, Italy

² Department of Otolaryngology, Ospedale e Casa di Cura Koelliker, Torino, Italy

³ Respiratory Clinical Research, Novartis Farma S.p.A., Origgio, Italy

Key words: Asthma. Nasal polyps. Anti-IgE. Quality of life.

Palabras clave: Asma. Pólipos nasales. Anti IgE. Calidad de vida.

The incidence of rhinosinusitis and nasal polyposis is higher among asthmatic patients, probably because the pathogenesis of both conditions is characterized by eosinophilic inflammation. Surgical treatment for polyps may be necessary when medical treatment is not effective, although relapses can occur even after surgery [1]. Omalizumab is a chimeric monoclonal anti-immunoglobulin E (anti-IgE) antibody, indicated for the treatment of difficult-to-control allergic asthma. It has also proven effective in patients with seasonal and perennial allergic rhinitis [2]. Anti-IgE may be effective in the treatment of refractory chronic rhinosinusitis [3], and a pilot study has shown that it may reduce the severity of the recurrence of nasal polyps [4].

We present the case of a 54-year-old man who was an ex-smoker (<10 pack-years) and had been affected by allergic asthma (sensitized to house dust mites and pollens) and chronic rhinosinusitis with nasal polyposis since the age of 42. Polyps were diagnosed in 1999, when he underwent bilateral microscopic radical sinus surgery because of the severity of his condition. In June 2006, the patient had a relapse of nasal polyposis and underwent functional endoscopic sinus surgery, with histological evidence of noneosinophilic nasal polyposis. At the follow-up visits, the ENT specialist prescribed repeated cycles of topical and systemic corticosteroids for the recurrence of nasal obstruction, hyposmia, and headache.

This patient also experienced asthma exacerbations almost once per month; consequently, his pulmonologist prescribed cycles of antibiotics and systemic corticosteroids. The patient had to stop practicing sports. He experienced nighttime awakenings and daytime symptoms, despite continuous high-dose therapy with inhaled corticosteroids and long-acting β_2 agonists (fluticasone 1000 μ g/salmeterol 100 μ g

and montelukast. Spirometry revealed moderate obstruction (forced expiratory volume in 1 second [FEV₁], 65%).

In April 2006, because of the persistence of the asthma symptoms, the pulmonologist prescribed omalizumab. The patient received 225 mg every 2 weeks (total IgE 294 IU/L, body weight 74 kg).

The patient's health gradually began to improve: he no longer experienced limitations on his daily activities or night awakenings, and he was able to reduce his need for a rescue bronchodilator. After 2 months, even forced sports activity was well tolerated, with no exertional dyspnea due to bronchospasm. The patient did not need any further periodical cycles of systemic corticosteroids, and his spirometry values showed a nonsignificant improvement (FEV₁, 69%).

An unexpected dramatic improvement in nasal symptoms (including hyposmia) was also observed. After the first dose of omalizumab, there was no further need for systemic or topical corticosteroids to control nasal symptoms. Congestion due to continuous recurrence of nasal polyps was successfully controlled. This striking efficacy was also confirmed by endoscopy findings, which revealed, for the first time in some years, normal mucosa with complete remission of the polyps and completely unobstructed nasal compartments (previous endoscopic examinations had revealed that the sinus mucosa was hyperplastic, with polypoid formations causing obstruction of the ostium-meatus complex).

The efficacy of this agent against nasal obstruction leads to a considerable improvement in quality of life for this type of patient, as nasal polyps are responsible for symptoms of nasal obstruction, excessive nasal secretions or mucopurulent postnasal drip, hyposmia, and anosmia with concomitant alterations in taste, sleep disturbances, headache, and facial pain. Furthermore, better control of rhinitis may facilitate control of asthma symptoms [5].

In conclusion, our observations and the evidence in the literature [3,4] lead us to suggest that, when nasal polyposis and allergic asthma co-occur, anti-IgE therapy could prove effective. Further studies should be performed to better evaluate the efficacy of this treatment in similar clinical conditions.

References

1. Fokkens W, Lund V, Bachert C, Clement P, Hellings P, Holmstrom M, Jones N, Kalogjera L, Kennedy D, Kowalski M, Malmberg H, Mullol J, Passali D, Stammberger H, Stierna P; EAACI. EAACI position paper on rhinosinusitis and nasal polyps executive summary. *Allergy*. 2005 May;60(5):583-601.
2. Berger WE. Treatment of allergic rhinitis and other immunoglobulin E-mediated diseases with anti-immunoglobulin E antibody. *Allergy Asthma Proc*. 2006 Mar-Apr;27(2 Suppl 1):S29-32.

3. Grundmann SA, Hemfort PB, Luger TA, Brehler R. Anti-IgE (omalizumab): A new therapeutic approach for chronic rhinosinusitis. *J Allergy Clin Immunol*. 2008 Jan;121(1):257-8.
4. Penn R, Mikula S. The role of anti-IgE immunoglobulin therapy in nasal polyposis: a pilot study. *Am J Rhinol*. 2007 Jul-Aug;21(4):428-32.
5. Canonica GW. Treating asthma as an inflammatory disease. *Chest*. 2006;130:21S-28S.

■ Manuscript received July 24, 2008; accepted for publication October 21, 2008.

Carlo Gulotta, MD

Pneumologia - Fisiopatologia Respiratoria
 AOU San Luigi Gonzaga
 Regione Gonzole, 10
 10043 Orbassano (TO), Italy
 E-mail: c.gulotta@sanluigi.piemonte.it



Benefits of Alpine Mountain Climate of Bavaria in Patients With Allergic Diseases and Chronic Obstructive Pulmonary Disease: Results From the AURA* Study

B Eberlein,^{1,2} A Gulyas,³ K Schultz,⁴ J Lecheler,⁵ S Flügel,³ C Wolfmeyer,⁴ K Thiessen,⁵ S Gass,⁴ M Kroiss,⁵ J Huss-Marp,¹ U Darsow,^{1,2} R Hollweck,⁶ T Schuster,⁶ H Behrendt,¹ J Ring²
¹ Division of Environmental Dermatology and Allergology, Helmholtz Center Munich for Environmental Health/TUM, Munich, Germany

² Department of Dermatology and Allergy Biederstein, Technische Universität München, Munich, Germany

³ Klinik Santa Maria, Oberjoch, Germany

⁴ Fachklinik Allgäu, Pfronten, Germany

⁵ Asthmazentrum Buchenhöhe, Berchtesgaden, Germany

⁶ Institute of Medical Statistics and Epidemiology, Technische Universität München, Munich, Munich, Germany

* Allergien und Umweltkrankheiten in der Rehabilitation

Key words: Climate therapy. Atopic eczema. Asthma. COPD.

Palabras clave: Terapia climática. Eczema atópico. Asma. EPOC.

Climate therapy takes advantage of specific climatic conditions to treat chronic diseases. In allergy, maritime and high-altitude mountain areas are of interest [1,2].

In this multicenter, prospective trial with no placebo group, objective and subjective parameters were determined in patients with atopic eczema, asthma, and/or chronic obstructive pulmonary disease (COPD) who were receiving treatment in 3 hospitals (Klinik Santa Maria, Oberjoch; Fachklinik Allgäu, Pfronten; Asthmazentrum Buchenhöhe, Berchtesgaden) offering in-patient rehabilitation in the alpine mountain climate of Bavaria.

Between August 2003 and December 2004, we studied 303 patients (165 children, 138 adults).

At the beginning (T1) and after 3 to 4 weeks (T2) of treatment we analyzed dermatologic parameters including grading of atopic eczema using the SCORing of Atopic Dermatitis tool (SCORAD) [3], skin function measurements (skin surface pH, sebum production, skin hydration, skin roughness), lung parameters (fractional exhaled nitric oxide [FE_{NO}], forced expiratory volume in 1 second [FEV₁], and, in children, the cold air hyperventilation provocation test), and exercise capacity (adults).

The patients completed the following questionnaires: Brief Symptom Inventory (BSI) [4], St. George's Respiratory Questionnaire (SGRQ) [5], Deutsches Instrument zur Erfassung der Lebensqualität bei Hauterkrankungen [German instrument for the assessment of quality of life in skin diseases] (DIELH) [6], 36-item short form general health questionnaire (SF-36) [7], the Eppendorf Itch Questionnaire (EIQ) [8] in adults, and the Revised Children Quality of Life Questionnaires for different age groups (KINDL) [9].

We determined the levels of the following: total immunoglobulin (Ig) E, eosinophils, eosinophil cationic protein (ECP), eotaxin, human thymus and activation-regulated chemokine (hTARC), and interleukin (IL) 16.

In all the study areas, the SCORAD results (mean [SD]) fell markedly from T1 to T2 (Table).

Sebum concentrations, stratum corneum hydration, and skin roughness showed no significant changes. Skin surface pH showed a significant increase in children in Berchtesgaden between T1 and T2 (5.1 [0.5] vs. 5.3 [0.5]), but not in adults or in patients in Oberjoch and Pfronten.

FEV₁ showed a significant increase in Oberjoch and Pfronten before and after lysis. FE_{NO} decreased significantly in children in Oberjoch and both in children and adults in Berchtesgaden (Table).

The cold air provocation tests in children showed a significant improvement in the percentage reduction in FEV₁ from 4.22% (4.64%) to 2.99% (2.69%) in Oberjoch and from 11.30% (12.02%) to 7.02% (7.17%) in Berchtesgaden ($P < .05$).

Values for the 6-minute walk test increased in asthmatic patients in Pfronten from 539.4 m (128.6) to 566.13 m (151.6) ($P = .055$) and in COPD patients from 429.9 m (170.1) to 478.82 m (182.39) ($P < .01$).

In the EIQ, the mean values of the affective and sensory items of the questionnaire did not differ significantly.

In Pfronten, all 11 BSI scores (eg, the global severity index: 1.57 [0.48] vs. 1.36 [0.40]; $P < .001$) and the SGRQ score decreased significantly, and all subparameters of the SF-36 questionnaire showed a significant increase (Table).

In Pfronten, the total score of the DIELH dropped significantly from 61.82 (28.39) to 49.48 (27.15) ($P < .02$), while subparameters did not differ. The KINDL score also improved: in Oberjoch, the eczema score (78.02 [15.53] vs 83.93 [14.60], $P < .05$) and the asthma score (79.08 [12.06] vs 81.03 [11.17], $P < .05$) increased significantly, as did the asthma score in Berchtesgaden (74.55 [15.84] vs 80.97 [11.34], $P < .01$).

Total IgE tended to decrease in Oberjoch (906.5 [1739.7] vs 866.2 [1669.1] kU_{A/L}, $P = .067$). Eosinophil counts (5.8 [3.4] vs 4.8 [2.4] $\mu\text{g/L}$) and ECP (24.0 [15.1] vs 21.7 [11.7] $\mu\text{g/L}$) decreased significantly between T1 and T2 in Berchtesgaden. Eotaxin and hTARC did not differ significantly. IL-16 dropped

Table. Results of Skin and Lung Parameters, the St George's Respiratory Questionnaire (SGRQ) and SF-36 at the Beginning (T1) and After 3 to 4 Weeks (T2) of Admission in the Different Study Areas^a

Children	T1	T2	Adults	T1	T2
SCORAD, score			SCORAD, score		
Oberjoch	31.4 (20.7)	15.9 (14.6) ^d	Pfronten	63.2 (19.3)	37.8 (17.5) ^d
Berchtesgaden	13.2 (13.4)	8.9 (10.7)	Berchtesgaden	24.3 (17.4)	16.8 (17.5)
FE _{NO} , ppm			FE _{NO} , ppm		
Oberjoch	25.0 (28.7)	16.0 (42.9) ^d	Pfronten	57.9 (58.6)	50.4 (40.9)
Berchtesgaden	43.2 (45.9)	21.1 (56.6) ^d	Berchtesgaden	25.6 (20.4)	16.5 (45.9) ^c
Children and Adults	T1 (Before Lysis)	T2 (Before Lysis)	T1 (After Lysis)	T2 (After Lysis)	
FEV ₁ , %					
Oberjoch	109.5 (14.6)	112.7 (13.4) ^d		115.6 (14.6) ^c	
Pfronten	60.9 (24.6)	68.2 (24.6) ^c		58.5 (22.0)	62.1 (23.4)
Berchtesgaden	84.2 (16.3)	91.6 (12.9)		92.0 (14.7)	97.6 (12.7)
Adults	T1	T2	T1	T2	
SGRQ			SF 36		
Symptom score			Physical role		
Pfronten	54.4 (23.6)	50.9 (21.9) ^b	Pfronten	43.4 (41.3)	70.2 (40.6) ^d
Berchtesgaden	37.8 (21.4)	30.1 (21.7)	Berchtesgaden	50.0 (26.7)	75.0 (33.3)
Activity score			Pain		
Pfronten	61.5 (22.6)	58.0 (23.1) ^b	Pfronten	68.2 (29.4)	79.4 (23.0) ^d
Berchtesgaden	36.4 (18.6)	30.7 (16.4)	Berchtesgaden	80.3 (20.5)	79.9 (16.9)
Impact score			Health perception		
Pfronten	36.7 (19.5)	30.6 (19.2) ^d	Pfronten	43.5 (18.9)	51.2 (21.2) ^d
Berchtesgaden	21.1 (13.6)	13.8 (11.6)	Berchtesgaden	55.6 (18.4)	63.1 (23.5)
Total score			Social function		
Pfronten	45.9 (19.8)	40.5 (19.2) ^d	Pfronten	75.2 (26.3)	85.4 (19.8) ^d
Berchtesgaden	26.3 (15.7)	21.2 (8.8)	Berchtesgaden	81.3 (23.8)	80.7 (25.8)
			Emotional role		
			Pfronten	72.1 (40.8)	87.6 (28.0) ^d
			Berchtesgaden	40.7 (43.4)	72.7 (38.9)

Abbreviations: FE_{NO}, fractional exhaled nitric oxide; FEV₁, forced expiratory volume in 1 second; ppm, parts per million; SCORAD, Severity Scoring of Atopic Dermatitis.

^a Values are expressed as the mean (SD).

^b $P < .05$ vs. T1

^c $P < .01$ vs. T1

^d $P < .001$ vs. T1

significantly in Pfronten (1541.4 [1865.4] vs 1213.7 [1701.4] pg/mL).

There were significant correlations between the SCORAD and skin hydration results ($P < .05$), FE_{NO} ($P < .05$), mean values of the affective and the sensory items of the EIQ ($P < .01$), and, in adults, between the SCORAD results and all the parameters of the DIELH ($P < .05$). We found no correlation between the SCORAD results and the values for sebum content, eotaxin, pH, SGRQ, or SF-36.

This study shows that rehabilitation treatment in specialized in-patient facilities in the alpine mountain areas of Bavaria [10] has a beneficial effect on inflammatory skin and lung diseases, with a clear improvement in quality of life.

Funding Source

Free State of Bavaria (Bayerisches Staatsministerium für Landesentwicklung und Umweltfragen, Bayerisches Staatsministerium für Arbeit und Sozialordnung, Familie und Frauen, Bayerisches Staatsministerium für Gesundheit, Ernährung und Verbraucherschutz, Regierung von Oberbayern)

The data were presented in abstract and poster form at the XXVI Congress of the European Academy of Allergology and Clinical Immunology, 9-13 June 2007, Göteborg, Sweden. Eberlein B, Gulyas A, Schultz K, Lecheler J, Flögel S, Wolfmeyer C, Thiessen K, Gass S, Kroiss M, Huss-Marp J, Darsow U, Hollweck R, Schuster T, Behrendt H, Ring J. **Benefits of alpine mountain climate of Bavaria in patients with allergic diseases – results from the AURA-study.** Allergy. 2007;62 (Suppl 83):156.

References

- Engst R, Vocks E. High-mountain climate therapy for skin diseases and allergy: Mode of action, therapeutic results, and immunologic effects. *Rehabilitation*. 2000;39:215-22.
- Schultze-Werninghaus G. Should asthma management include sojourns at high altitude? *Chem Immunol Allergy*. 2006;91:16-29.
- Kunz B, Oranje AP, Labrèze L, Stalder JF, Ring J, Taieb A. Clinical validation and guidelines for the SCORAD index: consensus report of the European Task Force on Atopic Dermatitis. *Dermatology*. 1997;195:10-19.

4. Derogatis LR, Melisaratos N. The Brief Symptom Inventory: an introductory report. *Psychol Med.* 1983;13:595-605.
5. Jones PW, Quirk FH, Baveystock CM, Littlejohns P. A self-complete measure of health status for chronic airflow limitation. The St. George's Respiratory Questionnaire. *Am Rev Respir Dis.* 1992;145:1321-7.
6. Schäfer T, Staudt A, Ring J. German instrument for the assessment of quality of life in skin diseases (DIELH). Internal consistency, reliability, convergent and discriminant validity and responsiveness. *Hautarzt.* 2001;52:624-8.
7. Ware JJ, Snow KK, Kosinski M, Gandek B: SF-36 Health Survey. Manual and interpretation guide. Boston, The Health Institute, New England Medical Center, 1993.
8. Darsow U, Mautner VF, Bromm B, Scharein E, Ring J. The Eppendorf Pruritus Questionnaire. *Hautarzt.* 1997;48:730-3.
9. Ravens-Sieberer U, Bullinger M. Assessing health-related quality of life in chronically ill children with the German KINDL: first psychometric and content analytical results. *Qual Life Res.* 1998;7:399-407.
10. Eberlein B, Gulyas A, Schultz K, Lecheler J, Flögel S, Wolfmeyer C, Thiessen K, Jakob T, Schuster T, Hollweck R, Ring J, Behrendt H. Domestic allergens and endotoxin in three hospitals offering in-patient rehabilitation for allergic diseases in the alpine mountain climate of Bavaria – the AURA study. *Int J Hyg Environ Health.* 2009; 212: 21-26.

■ Manuscript received August 13, 2008; accepted for publication October 20, 2008.

Prof. Dr. Bernadette Eberlein

Klinik und Poliklinik für Dermatologie und
Allergologie am Biederstein
Technische Universität München
Biedersteiner Str. 29
D-80802 München, Germany
E-mail: eberlein@lrz.tum.de

Allergic Contact Dermatitis to Polyethylene Terephthalate Mesh

H-L Lung,¹ L-H Huang,¹ H-C Lin,² S-D Shyur¹

¹Division of Allergy, Immunology and Rheumatology, Department of Pediatrics, Mackay Memorial Hospital, Taipei, Taiwan

²Department of Otolaryngology, Mackay Memorial Hospital, Taipei, Taiwan

Key words: Allergic contact dermatitis. Cochlear implantation. Mesh. Polyethylene terephthalate.

Palabras clave: Dermatitis de contacto alérgica. Implante coclear. Malla. Polietileno tereftalato.

A 4-year-old boy received a cochlear implant (Nucleus 24 Contour device, Cochlear Corporation, Sydney, Australia) over his left ear for bilateral congenital hearing loss. Sixteen days later, severely pruriginous erythema with serous discharge appeared over the central area of the skin flap (Figure, A). The lesion persisted for 3 months despite treatment with antibiotics and topical corticosteroids, and was eventually excised because of uncontrollable scratching. No leukocytosis or fever was noted. Infection was ruled out by negative bacterial culture and abundant lymphocyte infiltration in histopathologic analysis of excised tissue. Vascular involvement was also ruled out, given the central location and unchanged size of the lesion. The excision wound healed completely. However, 2 weeks later, erythema with the same features developed over the same area and persisted. It was decided to remove the device. The processor of the implant was exposed (without its fibrous capsule) and surrounded by gelatinous material (Figure, B), suggesting a persistent inflammatory reaction over the processor.

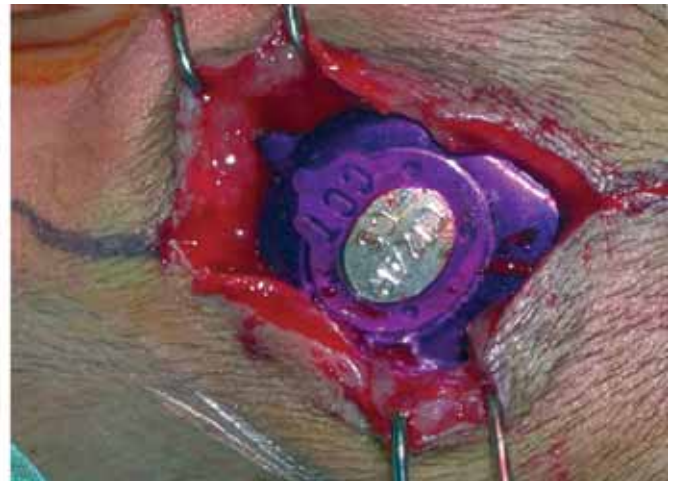
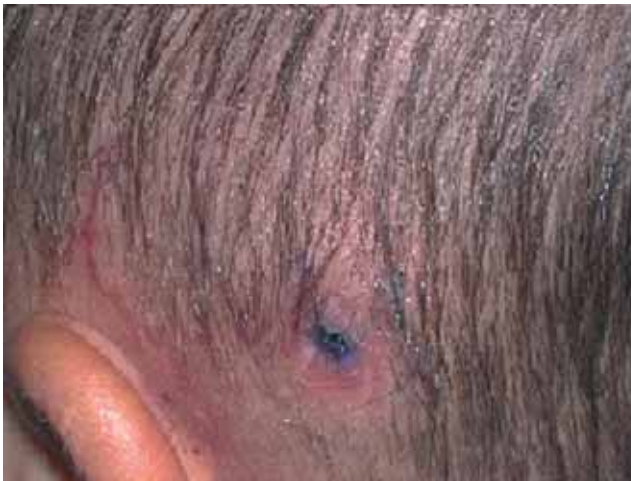
Figure. A, Severely pruriginous erythema with serous discharge ($2 \times 1 \text{ cm}^2$) over the central area of the skin flap. It appeared 16 days after implantation and persisted for 3 months. B, Immediate intraoperative finding during the removal procedure. The processor was exposed without its normal fibrous capsule and surrounded by gelatinous material.

The patient's immunologic workup was normal. Although rarely reported in the literature, contact dermatitis was suspected. A 48-hour closed patch test was performed on the patient's upper back. The European standard series, the Material Sample Kit of the Nucleus Cochlear Implant System (silicone elastomer HCRP-50, silicone LSR-30, RTV silicone adhesive, silicone Nusil 4515 tubing, polyethylene terephthalate mesh [PET], titanium, and platinum), as well as Dexon and nylon sutures were tested using a Finn Chamber holding device (Epitest Ltd Oy, Tuusula, Finland) and Scanpor tape (Alpharma AS, Norgesplaster Facility, Vennessla, Norway). Readings taken according to the International Contact Dermatitis Research Group (ICDRG) recommendations [1] revealed a positive reaction to the PET mesh on D2 and D3. Control patch tests were performed on 10 volunteers (3 males and 7 females; mean age 35.1 years; 4 with a history of atopic dermatitis and 6 healthy) using PET mesh. All volunteers had negative results. Patch tests were repeated 2 weeks later and yielded the same results.

A new Nucleus 24 Contour device (Cochlear Corporation) was implanted over the right ear 3 months later without PET mesh at the suggestion of the allergist; no further contact dermatitis was observed on the skin flap.

Allergic contact dermatitis (ACD) is an uncommon complication of cochlear implantation. In a few reported cases, ACD was caused by the silicone components of the devices, leading them to be removed [2,3].

ACD to polymeric materials is rare, despite their widespread use in surgery. Two cases of ACD to polypropylene suture have been reported: one had a strong positive reaction in a preoperative skin patch test [4], the other exhibited refractory eczematous dermatitis with a cutaneous-id reaction [5]. In yet another case, recurrent ACD with generalized symptoms was proven to be induced by the ethylene oxide used for sterilizing sutures [6]. There are also reports of allergic reactions to pure nylon fibers [7].

PET is a linear, thermoplastic polyester. It was first manufactured in the 1940s under the commercial name of Dacron. Its characteristic biostability comes from the hydrophobic aromatic groups and high crystallinity promoting resistance to hydrolysis, and the porous matrix encouraging tissue ingrowth [8]. A fibrous capsule has generally formed 4 weeks after implantation [9]. The current medical applications include implantable suture, surgical mesh, vascular graft, and cuffs for heart valves. De Mateo et al [10] reported a patient with ACD to a polyethylene de Quervain splint. Sugiura et al [11] suggested the antioxidants or lubricants added during manufacturing as the cause of contact urticaria to polyethylene gloves. Since polyester implants and prosthesis come in increasingly numerous varieties, it is advisable to test panels or sample kits before use and to choose the implant that is most compatible with the patient.

References

1. Fregert S. Manual of Contact Dermatitis. 2nd ed. Copenhagen. Munksgaard. 1981;71-6.
2. Puri S, Dornhoffer JL, North PE. Contact dermatitis to silicone after cochlear implantation. *Laryngoscope*. 2005;115:1760-2.

3. Kunda LD, Stidham KR, Inserra MM, Roland PS, Franklin D, Roberson JB. Silicone allergy: a new cause for cochlear implant extrusion and its management. *Otol Neurotol*. 2006;27:1078-2.
4. Sánchez-Morillas L, Reaño Martos M, Rodríguez Mosquera M, Iglesias Cadarso A, Pérez Pimiento A, Domínguez Lázaro AR. Delayed sensitivity to Prolene®. *Contact Dermatitis*. 2003;48:338-9.
5. Asherman JA, Hunter CJ, Bickers DR. Refractory eczematous dermatitis associated with retained suture material. *Ann Plast Surg*. 2006;56:205-7.
6. Dagregorio G, Guillet G. Allergic suture material contact dermatitis induced by ethylene oxide. *Allergy*. 2004;59:1239.
7. Fisher AA. Nylon allergy: nylon suture test. *Cutis*. 1994;53:17-8.
8. Feldman D, Hultman S, Colaizzo R, von Recum A. Electron microscope investigation of soft tissue ingrowth into Dacron velour with dogs. *Biomaterials*. 1983;4:105.
9. Schreuders P, Salthouse T, von Recum AF. Normal wound healing compared to healing within porous Dacron implants. *J Biomed Mater Res*. 1988;22:121-35.
10. De Mateo JA, Enrique E, Díaz Palacios MA, Castelló JV, Malek T. Contact dermatitis due to a 'de Quervain' splint. *Allergy*. 2003;58:828-9.
11. Sugiura K, Sugiura M, Shiraki R, Hayakawa R, Shamoto M, Sasaki K, Itoh A. Contact urticaria due to polyethylene gloves. *Contact Dermatitis*. 2002;46:262-6.

■ Manuscript received June 9, 2008; accepted for publication October 21, 2008.

Li-Hsin Huang

Division of Allergy, Immunology and

Rheumatology

Department of Pediatrics

Mackay Memorial Hospital

No. 92, section 2, Chung-shan North Road

10449 Taipei, Taiwan

E-mail: lilly@ms1.mmh.org.tw

An Alternative Approach to a Renal Transplant Patient Who Experienced an Immediate Type Systemic Reaction Due to Methylprednisolone Sodium Succinate

A Gelincik,¹ H Yazıcı,² T Emre,² F Yakar,³ S Buyukozturk¹

¹Allergy Division, Department of Internal Medicine, Faculty of Medicine, Istanbul University, Istanbul, Turkey

²Nephrology Division, Department of Internal Medicine, Faculty of Medicine, Istanbul University, Istanbul, Turkey

³Department of Chest Disease, Faculty of Medicine, Istanbul University, Istanbul, Turkey

Key words: Drug allergy. Immediate-type systemic reaction. Methylprednisolone sodium succinate.

Palabras clave: Alergia medicamentosa. Reacción sistémica de tipo inmediato. Succinato sódico de metilprednisolona.

Intravenous corticosteroids are frequently used to manage allergic reactions. Paradoxically, however, they can cause rare systemic reactions such as anaphylaxis. These reactions seem to be related to the kind of esters the drugs contain. As corticosteroids are poorly soluble in saline, they are coupled with esters such as phosphate ester and succinate ester, which make them water-soluble for intravenous application. In one report, anaphylactic reactions occurred after intravenous administration of succinate-containing corticosteroid preparations, and, in most patients, administration of phosphate-containing corticosteroids such as dexamethasone and betamethasone was found to be safe [1].

A 26-year-old man who was diagnosed with end-stage renal failure due to Alport syndrome was sent to our institution to receive a living-related donor renal transplant. On the second preoperative day, the patient was scheduled to be given 1000 mg of methylprednisolone sodium succinate (MPS) dissolved in 500 mL of normal saline in 4 separate doses, each lasting 30 minutes. Within the first 10 seconds of the initial intravenous infusion of MPS, the patient experienced discomfort and progressive dyspnea. Physical examination revealed bronchial obstruction, the infusion was stopped, and inhaled salbutamol was administered. The patient recovered, although surgery was postponed and a strategy was designed for further management. He had no history of atopy or asthma, and had never reacted adversely to any drug.

After a 6-week refractory period, skin prick tests and intradermal tests with MPS, dexamethasone acetate, and hydrocortisone hemisuccinate were applied stepwise until positive results were obtained (Table). The same procedure was applied to 10 atopic and 10 nonatopic subjects, and all were negative. The results of skin prick tests recorded at 20 minutes were compared with simultaneous negative and positive controls, (saline solution and histamine, each at 10 mg/mL, respectively), and the results of intradermal tests were compared using only saline solution as a negative control. The intradermal application of 0.02 mL of MPS and 0.02 mL of hydrocortisone hemisuccinate at a 1:100 dilution caused 35-mm and 6-mm wheal reactions, respectively, while skin tests with dexamethasone acetate were negative. The results of oral provocation tests with methylprednisolone tablets were negative, suggesting that the causative agent may have been the succinate compound in the parenteral preparations of methylprednisolone, and that the reaction was caused by

immunoglobulin (Ig) E-mediated hypersensitivity. Thus, the patient was successfully given intravenous dexamethasone as immunosuppressive therapy in the early posttransplantation period, and oral methylprednisolone afterwards.

Because of its therapeutic efficacy in controlling allograft rejection without causing undue toxicity, MPS is favored by most physicians treating renal transplant recipients [2]. To date, there have been 13 cases of anaphylactic or anaphylactoid reactions to MPS in renal transplant recipients. In most cases, the patients were atopic or asthmatic. Interestingly, the patient we report was not atopic. However, we may speculate that he could have been sensitized while receiving parenteral methylprednisolone. In 3 of the cases reported in the literature, an episode of rejection was further treated with oral prednisone, and in 1 case this was accompanied by hydrocortisone phosphate [3]. These findings suggest that succinate esters have immunologic potential. Corticosteroids probably only act as haptens because of their low molecular weight, and succinate ester has been suggested as a possible cause of selective antigenicity complexes [4].

In conclusion, clinicians should be aware that severe allergic reactions in response to intravenous MPS are rare, and skin testing against MPS prior to usage may help prevent further adverse reactions. The most appropriate approach in these patients seems to require phosphate-containing corticosteroids after skin testing.

References

1. Nakamura H, Matsuse H, Obase Y, Mitsuta K, Tomari S, Saeki S, Kawano T, Kondo Y, Machida I, Shimoda T, Asai S, Kohno S. Clinical evaluation of anaphylactic reactions to intravenous corticosteroids in adult asthmatics. *Respiration*. 2002;69:309-13.
2. Rao K, Andersen R, O'Brien T. Successful renal transplantation in a patient with anaphylactic reaction to Solu-Medrol (Methylprednisolone sodium succinate). *Am J Med*. 1982;72:161-3.
3. Saito R, Moroi S, Okuno H, Ogawa O. Anaphylaxis following administration of intravenous methylprednisolone sodium succinate in a renal transplant recipient. *Int J Urology*. 2004;11:171-4.
4. Venturini M, Lobera T, del Pozo M, Gonzalez I, Blasco A. Immediate hypersensitivity to corticosteroids. *J Invest Allergol Clin Immunol*. 2006;16(1):51-6.

Table. Drug Concentrations Used in Skin Tests

	Prick Tests		Intradermal Tests	
	1:10 dilution	Without dilution	1:1000 dilution	1:100 dilution
Methylprednisolone sodium succinate (40 mg/mL)	4 mg/mL	40 mg/mL	0.04 mg/mL	0.4 mg/mL
Hydrocortisone hemisuccinate (100 mg/mL)	10 mg/mL	100 mg/mL	0.1 mg/mL	1 mg/mL
Dexamethasone acetate (4 mg/mL)	0.4 mg/mL	4 mg/mL	0.004 mg/mL	0.04 mg/mL

■ Manuscript received July 16, 2008; accepted for publication October 21, 2008.

Aslı Gelincik, MD
Eytam Street, No: 31/5, Macka,
Istanbul, Turkey
E-mail: gelincik@istanbul.edu.tr

Immediate-Type Allergic Reaction to Cefuroxime: Cross-Reactivity With Other Cephalosporins, and Good Tolerance to Ceftazidime

S Varela Losada, C González de la Cuesta, M García Álvarez-Eire, C González González
Allergy Unit, Santa María Nai Hospital, Ourense Hospital Complex, Ourense, Spain

Key words: Allergy. Hypersensitivity. Cefuroxime. Ceftazidime. Cephalosporin.

Palabras clave: Alergia. Hipersensibilidad. Cefuroxima. Ceftazidima. Cefalosporina.

Only a small percentage (9.5%-13%) of cases of immediate-type hypersensitivity to cephalosporins have a positive response to penicillin determinants. Most patients (57.7%-63.2%) react only to the culprit drug, and 36.8%-42.3% react to several cephalosporins [1,2]. Recent studies using skin testing and in vitro testing point to the R1 side chain as the determinant of hypersensitivity reactions to cephalosporins [1]. We present the case of a patient who was allergic to several cephalosporins and tolerated ceftazidime.

A 23-year-old woman was referred to our allergy unit for an adverse drug reaction to cefuroxime. Five days before, on day 9 of treatment with cefuroxime (Zinnat, GlaxoSmithKline, Madrid, Spain) she developed an itchy maculopapular rash, throat tightness, and vomiting 5 minutes after taking a dose. The symptoms remitted spontaneously. Twelve hours later, 90 minutes after taking the next dose, she again developed an itchy maculopapular rash. She was treated in the emergency room, and recovered in 30 minutes. She had previously tolerated cefuroxime.

One month later, prick and intradermal skin tests were performed with benzylpenicilloyl polylysine (0.04 mg/mL, Diater, Madrid, Spain), minor determinant mixture (0.5 mg/mL, Diater, Spain), benzylpenicillin (10 000 IU), amoxicillin (20 mg/mL), ampicillin (20 mg/mL), cefuroxime (20 mg/mL), ceftazidime (20 mg/mL), cefotaxime (20 mg/mL), ceftriaxone (20 mg/mL), cefepime (2 mg/mL), cefazolin (20 mg/mL), and cefoxitin (20 mg/mL). A wheal diameter greater than 3 mm was considered positive (skin prick test), as was a more than 3-mm increase in the diameter of the initial wheal (intradermal skin test) accompanied by a flare.

Single-blind placebo-controlled challenges with oral amoxicillin (50, 200, 250 mg) and intramuscular ceftazidime (50, 200, 250 mg) were carried out at 60-min intervals.

The intradermal test with cefuroxime was positive (wheal diameter of 13 × 12 mm), as was the skin prick test with cefotaxime (wheal diameter of 15 × 5 mm) and ceftriaxone (wheal diameter of 5 × 4 mm). The remaining tests were negative. The patient tolerated amoxicillin and ceftazidime.

The history of immediate-type reaction and the intradermal test positivity to cefuroxime suggest a type 1 allergic reaction. The second episode was milder, probably, because the previous reaction had occurred only 12 hours earlier.

This patient had a selective response to cephalosporins with good tolerance to penicillin determinants and ceftazidime.

The positive skin test results with cefotaxime and ceftriaxone suggest cross-reactivity between these cephalosporins, probably due to the similar R1 side chain. The negative skin test results and the good tolerance with ceftazidime could be due to small differences in the R1 side chain (Figure).

A recent report described a patient who was sensitized to β -lactam antibiotics with a methoxymino group (cefuroxime, ceftriaxone, and cefotaxime), but not to ceftazidime (negative skin test results, challenge not performed), which has an alkoxymino group [3].

In a Spanish study of immediate-type allergic reactions to cephalosporins, cefuroxime was the most frequent culprit drug: of the 9 patients with positive results (skin test or radioallergosorbent test), 5 had selective responses and 4 experienced cross-reactivity between ceftriaxone and cefotaxime [1].

There is partial cross-reactivity between cephalosporins. Patients who are allergic to cephalosporins should undergo testing with other members of this group, as these drugs may be necessary in cases of severe infection.

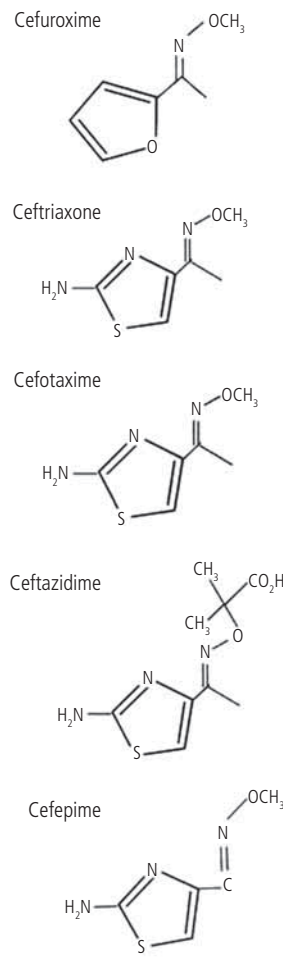


Figure. Chemical structure of the R1 side chains.

References

1. Antunez C, Blanca-López N, Torres MJ, Mayorgana C, Perez-Inestrosa E, Montañez MI, Fernández T, Blanca M. Immediate allergic reactions to cephalosporins: evaluation of cross-reactivity with a panel of penicillins and cephalosporins. *J Allergy Clin Immunol*. 2006;117:404-10.
2. Romano A, Mayorgana C, Torres MJ, Artesani MC, Suau R, Sánchez F, Pérez E, Venuti A, Blanca M. Immediate allergic reactions to cephalosporins: cross-reactivity and selective responses. *J Allergy Clin Immunol*. 2000;106:1177-83.
3. Hasdenteufel F, Luyasu S, Renaudin JM, Trechot P, Kanny G. Anaphylactic shock associated with cefuroxime axetil: structure-activity relationships. *Ann Pharmacother*. 2007;41:1069-72.

■ Manuscript received September 2008; accepted for publication October 24, 2008.

Susana Varela Losada

Unidad de Alergología
Hospital Santa María Nai
Complejo Hospitalario de Ourense
Rúa Ramón Puga, 52-54
32005 Ourense, Spain
susana.varela.losada@sergas.es

Monosensitization to *Blomia tropicalis*: Is Exposure the Only Factor Involved?

A Capriles-Hulett,¹ V Iraola,² H Pinto,² M Sánchez-Borges,³
M Daboín-De Veer,¹ E Fernández-Caldas⁴

¹Allergology Unit, Hospital San Juan De Dios, Caracas, Venezuela

²Laboratorios Leti, Madrid, Spain

³Allergy Service, Clínica El Avila, Caracas, Venezuela

⁴Allergy Innovations GmbH, Starnberg, Germany

Key words: *Blomia tropicalis*. *Dermatophagoides*. Dust mites. Allergic sensitization.

Palabras clave: *Blomia tropicalis*. *Dermatophagoides*. Ácaros del polvo doméstico. Sensibilización alérgica

Mite allergy is the most prevalent source of sensitization worldwide [1]. Mites thrive in climates with high humidity and temperature; *Blomia tropicalis* and *Dermatophagoides pteronyssinus* are commonly found in the mattresses of allergic patients in Caracas, Venezuela [2]. In patients attending allergy clinics, variable rates of isolated sensitization to *B tropicalis* have been reported [3,4]. We further explore this phenomenon and verify whether mattress mite fauna determines isolated sensitization to *B tropicalis*.

Two hundred consecutive patients with rhinitis and/or asthma attending allergy clinics from July 2006 to July 2007 were analyzed. The protocol was approved by the Institutional Review Boards of the participating institutions and patients signed informed consent forms. Skin prick testing was applied using glycerinated extracts at 100 HEP/mL of *D pteronyssinus* and *B tropicalis* (Leti Laboratories, Madrid, Spain), and readings taken 15 minutes after application were considered positive if a wheal of at least 3 mm greater than the glycerinated saline control was present. Histamine phosphate 1 mg/mL served as a positive control. Patients with positive skin test results to *B tropicalis* and negative results to *D pteronyssinus* were selected for study. Serum was stored at -20°C until analysis and tested for specific IgE to *D pteronyssinus*, *D farinae*, and *B tropicalis* using ImmunoCAP technology (UNICAP 100, Pharmacia AB Diagnostics, Uppsala, Sweden). Values higher than 0.35 kU_A/L were considered

positive [5]. Dust was collected by vacuum from mattresses that had been used by patients for at least 2 years (Mitest Filter Unit, INDOOR Biotechnologies, Charlottesville, Virginia, USA). Numbers and species of mites per gram of dust were determined using the flotation method [6]. Der p 1 and Der f 1 allergens in mattress dust were quantified using monoclonal antibodies (INDOOR Biotechnologies Ltd, Manchester, UK) and Blo t 5 was determined using an in-house 2-site enzyme-linked immunosorbent assay developed by the Asthma and Allergy Group of the National University of Singapore [7].

Only patients with positive skin test results to *B tropicalis* and negative results to *D pteronyssinus* (25/200, 12.5%) were selected. Twenty-five patients with a mean (SD) age 14.4 (11.6) years were studied. In vitro mite-specific IgE levels were completely consistent with the results of the skin prick tests (not shown). The numbers of mites per gram of dust and the percentages of mattresses with different mite species, as well as levels of Der p 1, Der f 1, and Blo t 5, are shown in the Table. Patients were exposed to high levels of Der p 1 and Der f 1, whereas lower quantities of Blo t 5 allergen were detected.

B tropicalis is a prevalent allergen that is indigenous to tropical areas, where a knowledge of mite fauna is of paramount importance [1,6]. The results of skin testing and bronchial/conjunctival challenge are clinically significant [8], and the low to moderate degree of cross-reactivity with the genus *Dermatophagoides* is particularly relevant for

Table. Quantification of Mites and Allergen Levels in Mattress Dust

Mites	Mites/g of dust	Mattresses, %	
Total	13 823.7 (22 774.4)	100	
<i>Dermatophagoides pteronyssinus</i>	3360.3 (6000.4)	100	
<i>Dermatophagoides farinae</i>	392.7 (776.6)	72.2	
<i>Blomia tropicalis</i>	7500.2 (14516.5)	88.8	
<i>Euroglyphus maynei</i>	637.6 (1540.1)	44.4	
<i>Suidasia</i> species	226.89 (921.4)	16.6	
<i>Anoetidae</i>	7.4 (31.7)	5.5	
<i>Cheyletus</i>	636.2 (1177.9)	55.5	
<i>Tarsonemus</i>	1390.0 (2483.3)	76.9	
<i>Demodex</i>	6.9 (25.2)	7.6	
<i>Prostigmata</i>	3.5 (12.8)	7.6	
<i>Oribatidae</i>	14.6 (36.3)	16.6	
Unknown	49.7 (154.0)	15.3	
Allergens	Detected in %	Mean (SD), µg/g of dust	Range
Der p 1	100	6.0 (6.4)	0.26-28.15
Der f 1	84.6	10.57 (13.15)	0.78-40.56
Blo t 5	38.4	0.48 (0.72)	0.02-2.15

the clinician [1]. The objective of the present study was to investigate mite fauna from the mattresses of patients who had positive results to skin prick tests with *B tropicalis* and negative results with *D pteronyssinus*.

We have previously observed isolated sensitization to *B tropicalis* [2,3]. Allergen levels corroborated significant infestation in mattresses of patients who had positive skin test results to *B tropicalis* and negative results to *D pteronyssinus* (Table). Skin test results correlated with those of specific IgE determinations, underlining the fact that patients with high exposure to both genera tended to respond only to *Blomia*. The unexpected lower levels of Blo t 5 detected could be due to the relative abundance and instability of Blo t 5 or the reliability of the assay used [6,7].

In conclusion, we found no direct relationship between exposure and isolated sensitization to *B tropicalis*. A high degree of indoor infestation, the existence of monosensitized patients, and relatively low cross-reactivity with the genus *Dermatophagoides* have implications for allergic patients in the tropics. Immunotherapy trials with *B tropicalis* should be performed.

References

1. Fernández-Caldas E, Lockey RF. *Blomia tropicalis*, a mite whose time has come. *Allergy*. 2004;59:1161-4.
2. Hurtado I, Parini M. House dust mites in Caracas, Venezuela. *Ann Allergy*. 1987;59:128-30.
3. Capriles-Hulett A, Sánchez-Borges M. *Dermatophagoides* and *Blomia* skin sensitization in allergic patients. Prevalence in a tropical environment. *Allergy Clin Immunol International* (J World Allergy Org) 2005;17:224-8.
4. Puccio FA, Lynch NR, Noga O, Noda A, Hagel I, Lopez E, Lopez R, Caraballo L, Mercado D, Di Prisco MC. Importance of including *Blomia tropicalis* in the routine diagnosis of Venezuelan patients with persistent allergic symptoms. *Allergy*. 2004;59:753-7.
5. Axen R, Drevin H, Kober A, Yman L. A new laboratory diagnostic system applied to allergy testing. In: Johansson, SGO, ed. *Proceedings of a Clinical Workshop "IgE Antibodies and the Pharmacia CAP System in Allergy Diagnosis"*. Uppsala, Sweden: Pharmacia Publication 1988;3-5.
6. Fernández-Caldas E, Puerta L, Mercado D, Lockey RF, Caraballo LR. Mite fauna, Der p I, Der f I and *Blomia tropicalis* allergen levels in a tropical environment. *Clin Exp Allergy*. 1993;23:292-7.
7. Yi FC, Lee BW, Cheong N, Chua KY. Quantification of Blo t 5 in mite and dust extracts by two-site ELISA. *Allergy*. 2005;60:108-12.
8. Garcia Robaina JC, Sanchez Machin I, Fernandez Caldas E, Iraola Calvo V, Vazquez Moncholi C, Bonnet Moreno C, de la Torre Morin F. Skin tests and conjunctival and bronchial challenges with extracts of *Blomia tropicalis* and *Dermatophagoides pteronyssinus* in patients with allergic asthma and or rhinoconjunctivitis. *Int Arch Allergy Immunol*. 2003;131:182-8.

■ Manuscript received September 23, 2008; accepted for publication October 24, 2008.

Arnaldo Capriles-Hulett

PO Box 025323
Miami, Florida, 33102, USA
E-mail: arnaldocapriles@cantv.net

ERRATUM:

"Emedastine Difumarate Inhibits Histamine-Induced Collagen Synthesis in Dermal Fibroblasts"

Murota H, Bae S, Hamasaki Y, Maruyama R, Katayama I
J Invest Allergol Clin Immunol 2008;18(14):245-52.

The unit of dosage for emedastine difumarate in this article appeared as "mg/mL". It should be "ng/ml".